Cerebral Arterial Gas Embolism and Treatment with intravenous Perfluorocarbon Emulsions (Oxycyte®) in Rats

Jiepei Zhu, John T. Parsons, Cameron R. Smith, Kandice L. Klepper and Bruce D. Spiess

Departments of Anesthesiology, and VCURES- Virginia Commonwealth University Reanimation Engineering Shock Center, School of Medicine, Virginia Commonwealth University, Richmond VA 23298-0695

ATACCC 2009

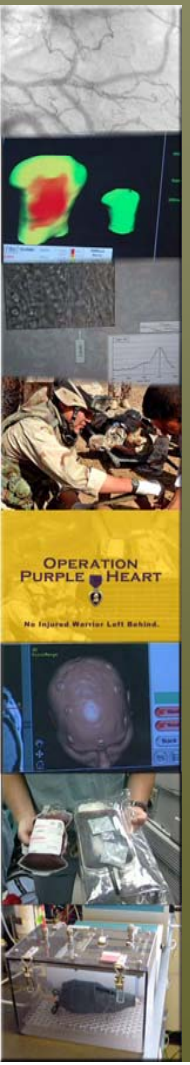

Introduction

Arterial gas embolism (AGE) is a common consequence of decompression illness (DCI) [1, 2] and often been seen in many surgical procedures such as cardiopulmonary bypass, neuro-and lung surgery. Cerebral AGE may result in brain functional deficits with long-term morbidity if the treatment is not promptly. Perfluorocarbon emulsions (PFC) is an oxygen carrier. Intravenous PFC infusion has shown the protect effects in experimental AGE [3] and DCI [4] by increase of tissue oxygenation and clearance of body gas [5]. The Objective of this study is to develop an experimental cerebral AGE model in rodent and test whether oxycyte (third generation of PFC) treatment after AGE will reduce brain damage and improve the outcome of the cerebral AGE.

Methods

Subjects & Groups: Male Sprague-Dawley rats (300 – 350 g body weight) are used for this study. Animals were housed in an environmentally controlled room at 22°C on a 12-hour dark/light cycle with food and water ad libitum. They were acclimatized for at least 2 days prior to experimentation. Individual animals were randomly assigned to one of following groups: 1) Sham Group, animals experienced all experimental procedures, except the internal carotid arterial gas emboli injury (AGE). 2) Cerebral AGE treated with saline group. 3) Cerebral AGE treated with PFC group. Animals were allowed to survival for 6 hours, 24 hours and 15 days after cerebral AGE.

Surgical procedures & hemodynamic monitoring: Animals were anesthetized with 4% isoflurane for 4 minutes, then tracheal tube was intubated . Anesthesia was maintained with 2% isoflurane. Toe pinch and corneal reflexes were assessed every 15 minutes to ensure adequacy of anesthesia. Core temperature was maintained at 37.0 ± 0.50°C, using an animal homeothermic heating system (Harvard Apparatus, Inc). Rats were ventilated with mixed 30% oxygen and 70% nitrogen and maintained with arterial blood CO2 level at 35 ± 3 mmHg. The right carotid and tail arteries were cannulated with polyethylene (PE 10 and PE 50) catheters for cerebral AGE and monitoring arterial blood pressure. Tail vein was also placed with PE10 catheter for PFC or saline treatment. In some cases, Licox oxygen probe was placed into right hemisphere for brain oxygen tension monitoring. (Fig. 1) Arterial and venous pressures, electrocardiogram (ECG, lead III) data were digitized and collected to hard disk via a data acquisition software package (Acknowledge®; Biopac Systems, Inc.; Goleta, CA) at a sampling frequency of 150 Hz. The software was used to calculate mean arterial pressure (MAP) and mean heart rate. Carpefen (8 mg/kg) was given intraperitonium injection(i.p.) before surgical procedures for pain control.

Cerebral Arterial Gas Embolism (CAGE) and Perfluorocarbon Emulsion Admission: Animals were stabilized for ten minutes after the surgical procedures. AGE was delivered through external carotid artery into internal carotid artery (total gas amount from 20 µl to 100 µl in two or three bolus). At 10 minutes post AGE, animals were given PFC (6 ml/kg, or 3.6 g/kg Oxycyte®, 60% v/w, Oxygen Biotherapeutics, Inc., California) or 0.9% saline over 15 minutes. When PFC treatment started, animal's breathing gas was changed to 100% oxygen to maximize PFC's oxygen carry capacity. When the treatment completed, all incisions were sutured and animal were woke up from anesthesia. Animals would consciously breathe 100% oxygen in chambers up to 4 hours after AGE. Animals would be survival for 6 hours, 24 hours and 15 days after cerebral AGE.

Assessment of Brain Tissue: Animals were euthanized and brain were collected for histopathological assessment, which included: TTC (Triphenyltetrazolium chloride) staining for ischemic infarct area, Fluoro-Jade staining for degenerated neurons and IgG immunohistochemistry staining for vascular endothelial cell damage and leakage of BBB.

CAGE Model development

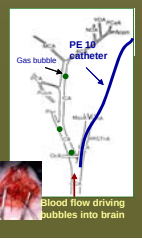

Blood flow driving bubbles into brain

Licox probe measure brain PO_2

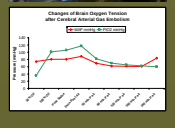

Biopac recording Bp and ECG

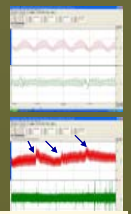

showed AGE caused systemic Bp increase

Survival rats breath 100% O_2 for 4 hrs after AGE

Results

- Gas volume of cerebral arterial gas embolism (CAGE) > 50 µl would cause massive brain damage, and animal could not recover from isoflurane.
- Histopathological assessment showed that CAGE caused multi-foci ischemic brain damage located in frontal cortex, forebrain, thalamus, some showed in hippocampus.
- All survival injured animals showed the weak movement on contralateral limbs especially on front limb, however, sham animals did not show movement deficit.

TTC staining | *Giemsa staining* | *IgG staining*

Saline Treatment at 10 min post CAGE

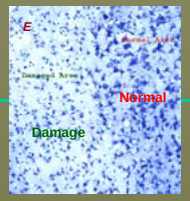

Objective = 10 X

Oxycyte Treatment at 10 min post CAGE

Figure A & B: TTC staining showed the ischemic infarct damage (arrows); Giemsa staining confirmed that TTC stained damage regions by arrows (C, D and E). IgG immunohistochemistry staining (F & G)demonstrated that CAGE can damage blood brain barrier (BBB), black color region indicated the IgG positive area. Comparing saline and PFC treatment, PFC treated animals showed less brain damage.

Figure H & J: Fluoro-Jade showed the damaged hippocampal ( ) & cortical neurons ( ) at 24 hr of AGE, Rx with saline.

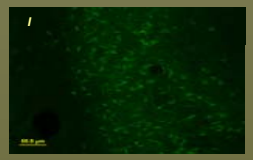

Figure K: Fluoro-Jade showed the damaged cortical neurons at 24 hr of AGE, Rx with Oxycyte.

Experimental timeline

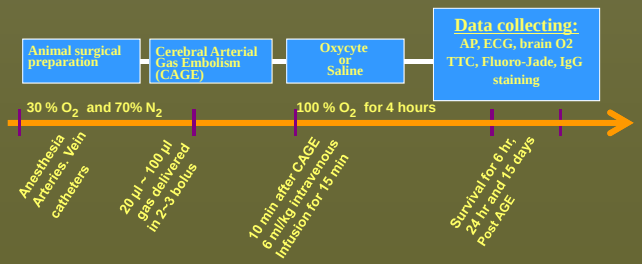

Summary

Cerebral arterial gas embolism (CAGE) will cause a decrease brain oxygen tension due to blockage of brain blood flow.

Multi-foci ischemic neuronal damage were shown after CAGE. Massive CAGE (>50 µl in current rodent model) may result in a severe brain damage (such as persistent vegetative state, coma or death).

Post-CAGE intravenous PFC treatment showed a reduced brain damage due to increase of oxygen delivery to damaged tissue. This protective effect may extend the therapeutic time frame for other therapeutic intervention or medical transportation.

References

1. *Aksoy FG MR imaging of subclinical cerebral decompression sickness. A case report Acta radiologica Acta Radiol. 2003 Jan;44(1):108-10*
2. *L AFÈRE P, G ERMONPRÉ P, B ALESTRA C. Pulmonary barotrauma in divers during mergency free ascent training: review of 124 cases. Aviat Space Environ Med 2009; 80: 371 – 5 .*
3. *Spiess BD, Braverman B. et al,. Protection from cerebral air emboli with perfluorocarbons in rabbits. Stroke 1986 17(6):1146-9.*
4. *Spiess BD., Perfluorocarbon emulsions as a promising technology: a review of tissue and vascular gas dynamics.J Appl Physiol. 2009 Apr;106(4):1444-52. Review.*
5. *Zhu, J., Hullett, JB., Somera, L., Barbee, RW., Ward, KR., Berger, BE. and Spiess, BD. Intravenous perfluorocarbon emulsion increases nitrogen washout after venous gas emboli in rabbits. Undersea & Hyperbaric Medicine. 2007 34(1) 7-20.*

Acknowledgements: *Funded by Office of Naval Research Grants N000140810474*