Fibrin: Promising New Target for Treatment of Acute Respiratory Distress Syndrome (ARDS) following Inhalation Injury

Kerfoot P. Walker III,[1] Steven Idell,[2] Andriy I. Batchinsky,[1] Kathy Koenig,[2] Zissis C. Chroneos,[2] Andrey A. Komissarov,[2] Krishna K. Midde,[2]
Corina Necsoiu,[1] Ruth Nguyen,[1] Michael L. Lucas,[1] Michael R. Scherer,[1] Michael A. Dubick,[1] Kevin K. Chung,[1] Leopoldo C. Cancio.[1]
[1]US Army Institute of Surgical Research, Ft. Sam Houston, Texas, 78234-6315
[2]University of Texas Health Science Center at Tyler, Tyler, Texas, 75708-3154

The use of Army medical and/or other Army records in the preparation of this material is acknowledged, but is not to be construed as implying official Department of the Army approval of the conclusions presented.

Introduction

Inhalation injury is a significant clinical problem that is commonly seen in both combat casualties as well as in civilian burn victims. **The rate of inhalation injury in combat casualties with burns from Iraq (approx. 15%) is twice as high as it is for civilians.** Many patients with inhalation injury develop a particularly severe form of Acute Lung injury (ALI) called the Acute Respiratory Distress Syndrome (ARDS). Inhalation injury is associated with considerable respiratory impairment, protracted hospitalization and the requirement for mechanical ventilation. Long-term complications of inhalation injury include protracted respiratory morbidity due to bronchial reactivity, accelerated pulmonary fibrosis and bronchiectasis. The mortality rate of ARDS including that associated with inhalation injury approaches 40 percent [1]. Inhalation injury is also associated with the early development of intrabronchial casts that originate from smoke-induced airway injury. These fibrinous casts interfere with gas exchange, often require bronchoscopic clearance and promote atelectasis of distal alveolar units. The purpose of this study was to determine the role of fibrin in inhalation injury, as a potential target for new drug therapies

Objectives

Determine the effects of wood bark smoke (WBS) on: (1) extravascular fibrin deposition, (2) induction of apoptosis, (3) plasminogen activator inhibitor-1 (PAI-1) expression at the protein and mRNA levels and (4) the stability of PAI-1 mRNA in porcine primary fibroblasts, mesothelial and epithelial cells .

Materials and Methods

- Swine (*Sus scrofa domestica*)(n=17, weight 40.0 +-1.1 kg SEM) were anesthetized (ketamine/midazolam/propofol), intubated, and mechanically ventilated for 48 hrs post injury.
- The injury consisted of exposure to cooled wood bark smoke mixed with 33% oxygen.
- Bronchoalveolar lavage (BAL) samples (3 x 20ml saline) were collected via an Olympus bronchoscope at baseline, 24h, and 48h.
- Post mortem samples collected from the left lung included pleural fluid, tissue placed immediately into Dulbecco's Modified Eagle Medium/10% Fetal Bovine Serum/Penicillin/ Streptomycin/ Amphotericin B, and formalin fixed tissue samples from proximal, medial, and distal areas of the lower lobe.
- Immunohistochemical analysis of fibrin, PAI-1, and Terminal Deoxynucleotidyl Transferase Mediated dUTP Nick End Labeling (TUNEL) analysis to identify epithelial cell apoptosis was performed on tissue obtained in the necropsy.
- Western blot analysis was performed on conditioned media from fibroblasts, epithelial and mesothelial cells propagated from pleural fluid and lung tissue and exposed to wood bark smoke extract (WBSE).
- mRNA expression was determined by RT-PCR for WBSE exposed and control vehicle exposed fibroblasts, mesothelial and epithelial (alveolar type II) cells.

Observations

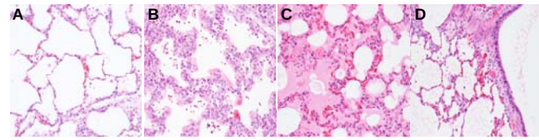

Figure 1. Immunohistochemical evidence of prominent alveolar fibrin deposition in pigs with inhalation injury. *A.* Ventilated porcine lung with moderate widening of airspaces and intact alveolar septa. *B.* Smoke injured porcine lung with marked widening of airspaces, interstitial thickening, hyaline membranes, and infiltration of leukocytes. *C.* Smoke injured porcine lung with severe edema. *D.* Smoke injured porcine lung with fibrinous network in airspaces and conducting airways.

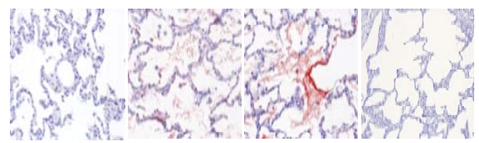

Figure 2. Immunohistochemical analysis of fibrin in porcine analysis. Prominent fibrin deposition was detected in the large and small airways and in the alveolar compartment.

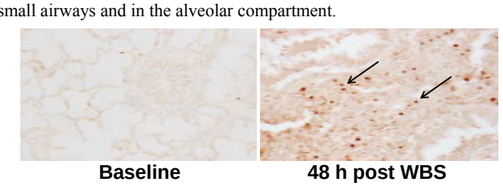

Figure 4. Apoptosis assessments in smoke injured animals. Histologic examination of TUNEL stained slides of porcine lungs revealed immunonegative staining in the baseline animals and nuclear positivity in the interstitium and lung parenchyma of burn injured animals. Apoptotic cells were observed in the lung epithelium and interstitium of the animals with inhalation injury. Little apoptotic change was observed in the lung tissues from ventilated control animals.

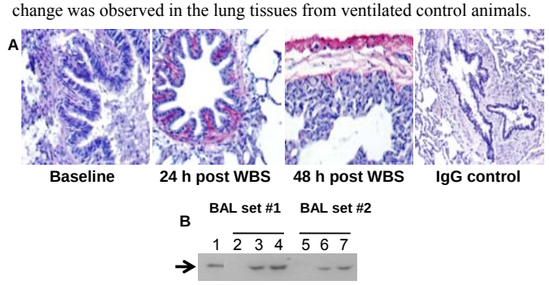

Figure 3. PAI-1 expression in smoke injured animals. *A.* Immunohistochemical analysis of PAI-1 in porcine lungs revealed immunonegativity in the baseline animals, immunopositivity in the subbronchus of 24h post smoked animal and immunopositivity in the subpleura of 48h post smoked animal. *B.* Western blot analysis of porcine BAL for PAI-1 expression. 50µl of porcine BAL was separated on 10% SDS-PAGE gel followed by transfer of the protein onto nitrocellulose membrane. The membrane was blocked with 1.0% BSA and PAI-1 was detected using rabbit polyclonal PAI-1 AB. Lane 1 recombinant PAI-1 (10ng), lanes 2 & 5 are Baseline, lanes 3 & 6 are 24h, and lanes 4 & 7 are 48h post WBS showing induction of PAI-1 in ALI.

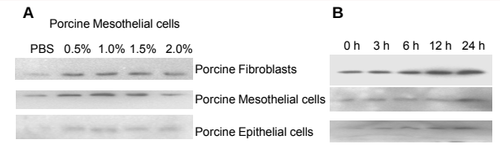

Figure 5. PAI-1 expression in WBSE exposed porcine primary cells by Western blot analysis. *A.* Conditioned media from porcine primary cells exposed to different doses of wood bark smoke extract was resolved on 10% SDS-PAGE gel. The separated proteins were then transferred on to nitrocellulose membrane followed by PAI-1 antigen detection using rabbit polyclonal PAI-1 AB. *B.* 50µl of conditioned media from porcine cells exposed to 1.0% WBSE in a time dependent manner was analyzed for PAI-1 antigen by western blotting. The blots in each the panels are representative of duplicate experiments and show dose and time-dependent induction of PAI-1 in resident lung cells exposed to WBS.

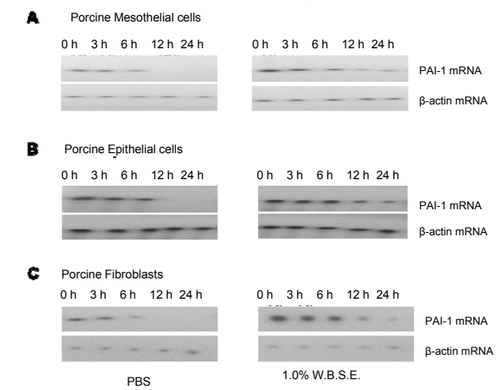

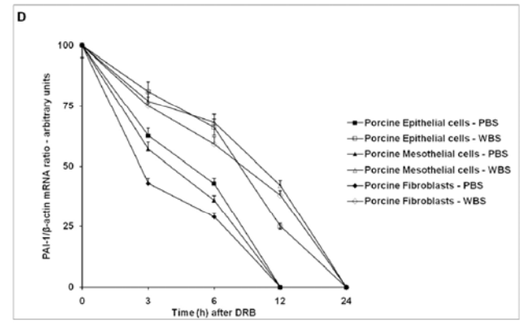

Figure 6. Stability of PAI-1 mRNA after WBSE in transcription chase experiments. Porcine primary cells were exposed to PBS (left panels) or 1.0% WBSE (right panels) for 3 hours followed by blocking ongoing transcription with 5,6-dichloro-1-β-D-ribofuranosyl-benzimidazole (DRB) (20µg/ml) and actinomycin (5µg/ml) at the indicated time intervals. Total RNA was isolated and reverse transcribed. All the blots were representative of duplicate experiments. These experiments show that PAI-1 mRNA stability is increased in resident lung cells after exposure to WBS and that the response uniformly occurs in lung ATII cells, lung fibroblasts and pleural mesothelial cells, plotted in panel D. The increased stability of PAI-1 mRNA underlies increased expression of PAI-1 protein in these cell types and suggests that the mechanism is operative in animals with inhalation injury.

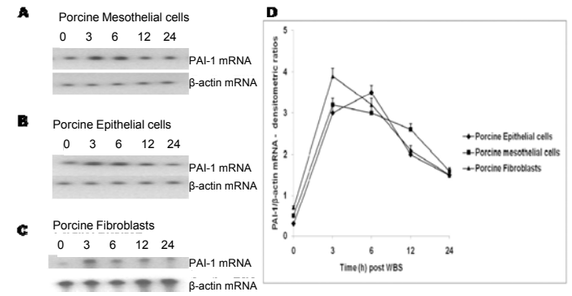

Figure 7. Time dependent PAI-1 mRNA expression in porcine primary cells exposed to 1.0% WBSE Total RNA was isolated by phenol chloroform extraction after the indicated time intervals. 5µg of total RNA was subjected to reverse transcription PCR for 45 minutes at 42˚C. RT product was PCR amplified for 30 cycles using porcine PAI-1 and β-actin primers followed by separation of the PCR product on 5.0% urea gel. The gel was later dried for 2hr and autoradiographed overnight at -80˚C. The blots in all the panels are representative of two sets of experiments , as plotted in panel D.

Conclusions

- Extravascular fibrin deposition and increased expression of PAI-1 characterize inhalation injury
- Upregulation of the major inhibitor of fibrinolysis, PAI-1, occurs in the lungs of animals with inhalation injury and potentiates extravascular fibrin there .
- The upregulation of PAI-1 mRNA precedes induction of PAI-1 protein by resident lung cells and is in part due to stabilization of the PAI-1 mRNA.
- The findings provide a rationale for fibrinolytic therapy.
- The data presented here suggests that potentially the new fibrinolysin called single chain urokinase plasminogen activator (scuPA) which resists inhibition by PAI-1 and exerts relatively durable fibrinolytic activity [2] may be a promising treatment modality for combat casualties with inhalation injury.

References

1. Phua, J., J. R. Badia, N. K. Adhikari, J. O. Friedrich, R. A. Fowler, J. M. Singh, D. C. Scales, D. R. Stather, A. Li, A. Jones, D. J. Gattas, D. Hallett, G. Tomlinson, T. E. Stewart, and N. D. Ferguson. 2009. Has mortality from acute respiratory distress syndrome decreased over time?: A systematic review. *Am J Respir Crit Care Med. 179:220-227.*
2. Komissarov A.A., Mazar A.P., Koenig K., Kurdowska A, and Idell S. Regulation of intrapleural fibrinolysis by urokinase-alpha-macroglobulin complexes in tetracycline-induced lung injury in rabbits. *Am J. Physiol Lung Cell Mol. Physiol.(In press).* 2009.

Acknowledgements

We would like to thank Shanmugasundaram Natesan Ph.D., and Robert J. Christy, Ph.D. for their essential contributions in the development of the epithelial cell isolation procedure. We are also grateful for the help provided by Belinda L. Meyers, Alisa Leon, Fanolua Faraimo, Hobart G. Perry, Michael J. Howard, Timothy E. Wallum, and Stephanie L. Truss in the daily administration of the experiments. NIH PO-1 **HL 076406 (SI, AAK, KK)**