Safety Evaluation of New Hemostatic Agents, WoundStat™ and Combat Gauze ™, in a Vascular Injury Wound Model in Swine

Bijan S. Kheirabadi, James E. Mace, Irasema B. Terrazas, Chriselda G. Fedyk, J. Scot Estep, Michael A. Dubick and Lorne Blackbourne

United States Army Institute of Surgical Research, Fort Sam Houston, TX 78234-6315

The use of Army medical and/or other Army records in the preparation of this material is acknowledged, but is not to be construed as implying official Department of the Army approval of the conclusions presented.

Introduction

Two new hemostats, WoundStat (smectite granules, WS) and Combat Gauze (kaolin-coated gauze, CG) were recently marketed for patient use (without prescription) after receiving FDA clearance as safe and effective agents for temporary treatment of external wounds with moderate to severe bleeding.

Our previous experimental studies demonstrated that WS and CG are the most efficacious hemostatic agents available for control of arterial hemorrhage and have potential utility for treating life-threatening hemorrhage in combat wounds. The new agents were much more effective than those previously deployed to battlefields (QuikClot and HemCon bandage).

Neither WS nor CG is biodegradable and similar to the other hemostatic agents must be removed from wounds before definitive surgical repair. We found that removal of CG was an easy procedure, but cleaning WS clay and removing all the material from the wound required extensive debridement. Despite our through debridement of groin wounds, microscopic residues of WS still remained in the lumen of injured arteries and had the potential to cause thrombosis if blood flow had been restored. Traces of kaolin powder from CG were also detected in one specimen. These findings were the rationale for performing this preliminary safety study in a new experimental model.

Objectives

To investigate the potential thrombogenicity and the risk of embolism of WS granules and kaolin particles of CG when these products are used to control bleeding in an external wound with major vascular injuries.

Methods

- Anesthetized pigs (n=24) were instrumented for blood sampling, fluid infusion, and monitoring of vital signs.
- An incision was made in the neck area; ~ 5-cm segments of the right carotid artery and the external jugular vein were isolated, clamped, and partially transected (Fig 1, a & b).
- Free bleeding was allowed for 30 seconds; wounds were then packed with gauze (Kerlix, n=8), CG (n=8) or WS (n=8) and compressed until bleeding stopped (Fig 1, c). Agents were kept in the wound for 2 hrs.
- Normal blood pressure (baseline) was restored by intravenous injection of 500 ml of Hextend fluid.
- Two hours after treatment, the vessels were reclamped and the wounds debrided according to standard clinical procedure (Fig 1, d).
- Blood vessels were primarily repaired by suturing (7-0 Prolene), blood flow was restored after infusion of 1 L Lactated Ringer's, and neck wound was closed (Fig 1, e & f); no heparin or aspirin was given to any of the pigs during the experiments.
- Two hrs later, blood flow through the repaired vessels was examined by CT scanning and direct observations; the vessels and vagus nerve were then recovered for histological examination.
- Animals were then euthanized; lung and brain tissues were recovered and examined for evidence of thromboembolism.

Results

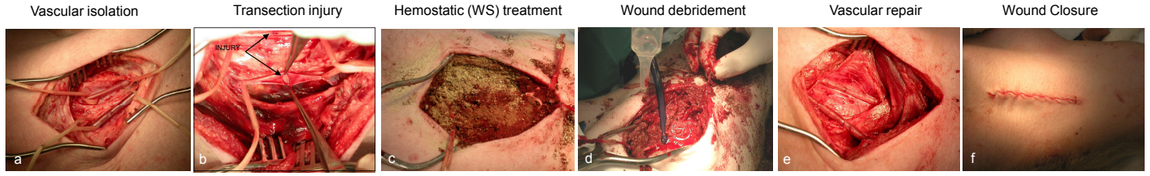

Fig 1: External wound model with vascular injuries.

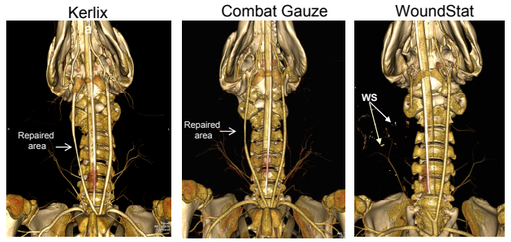

Fig. 2. CT images of left (intact) and right (treated) carotid arteries.

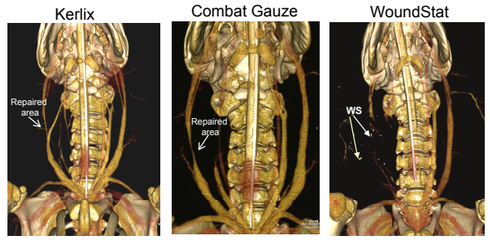

Fig. 3. CT images of left (intact) and right (treated) jugular veins.

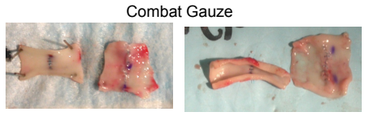

Fig. 4. CG-treated arteries and veins 2hrs blood reflow.

Fig. 5. WS-treated arteries and veins 2hrs after blood reflow.

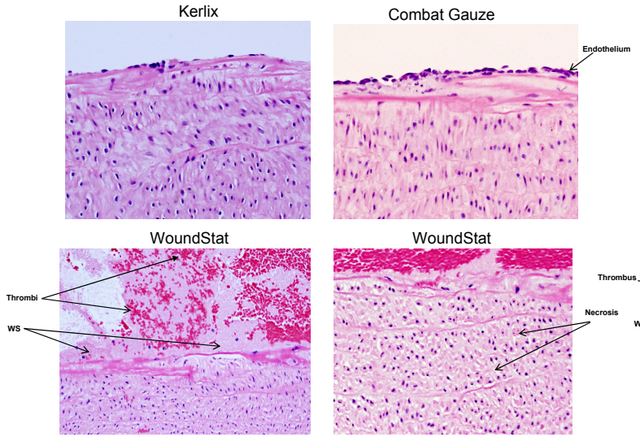

Fig. 6. Micrographs of **carotid arteries** treated with different agents.

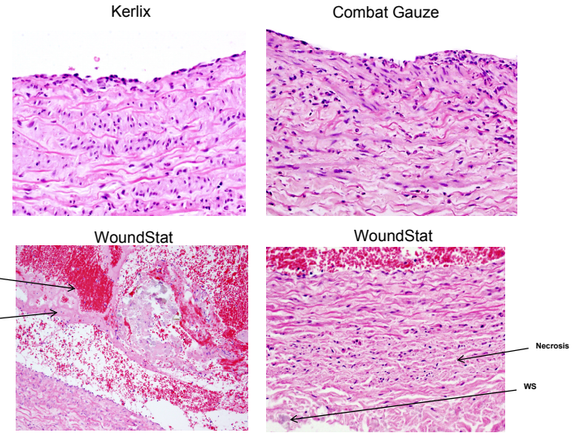

Fig. 7. Micrographs of **jugular veins** treated with different agents.

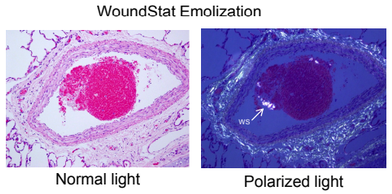

Fig. 8. Embolized WS residues and associated arterial thrombosis in lung.

Summary

- CT images and direct observation of the vessels showed essentially no difference between the vessels treated with Kerlix or CG. All the vessels were patent with some constriction in the sutured area (Figs. 2, 3). No thrombus or blood clot was found in the lumen or on the suture line of these vessels after recovery (Fig. 4).
- In contrast, CT images of vessels treated with WS showed no blood flow in 7 out of 8 arteries and 6 out of 8 veins (Figs. 2, 3). Large blood clots were found in the lumen of vessels occluding the entire treated segments (Fig 5).
- Gross inspection of brain and lung tissues (sliced) found no abnormality in Kerlix and CG groups. A large blood clot and a few WS residue were found in the lungs (2) of WS-treated pigs.
- The histological changes of CG and Kerlix vessels were minimal and equivalent to each other with no intraluminal thrombosis. Significant endothelial and transmural damages were found in WS-treated vessels with luminal thrombi and embedded WS residues (Figs 6, 7).
- Microscopic WS residues were also found in several regions of one lung which a few were associated with an arterial thrombosis (Fig. 8).

Conclusion

- No clinically significant change was found in blood vessels and distant organs of the pigs that were treated with CG or regular gauze 2 hours after vascular repair and blood flow.
- WS treatment, however, caused severe endothelial injury and significant transmural damage that rendered the vessels nonviable for primary surgical repair.
- WS residues were embolized in venous circulation and trapped in the lung with associated thrombosis.
- Given these significant adverse effects, WS should not be considered for treatment of external wounds with major vascular injuries particularly when safer and equally effective agent such as CG is currently available.
- The long-term safety of CG must be investigated in experimental survival studies and closely monitored in patients whose wounds are treated with this agent.

This study was funded by the US Army Medical Research and Materiel Command