Intravascular Temperature Management in a Patient with Raynaud's Disease During Major Burn Surgery

Peter A .DeSocio, DO†; Jason Capra, MD*; Booker T. King, MD†; Christopher V. Maani, MD†

†United States Army Institute of Surgical Research, Fort Sam Houston TX

*Department of Anesthesiology, San Antonio Uniformed Services Health Education Consortium, Fort Sam Houston, Texas

The opinions or assertions contained herein are the private views of the authors and are not to be construed as official or as reflecting the views of the Department of the Army or the Department of Defense.

Introduction

Burn patients with greater than 20% total body surface area [TBSA] burn are prone to hypothermia. Intravascular temperature management [IVTM] has been used to treat acute stroke, traumatic brain injury, and cardiopulmonary arrest; however, only in the context of deliberate hypothermia.

The historical goal has always been to cool patients, but the technology is now being applied in burn surgery to maintain normothermia.

Patients with Raynaud's disease (RD) and severe burns deserve special attention when describing management of perioperative normothermia. RD is a vasculopathy that often results in ischemia of the distal extremities when core temperature falls.

Hypothermia is often seen during major burn surgery. IVTM may help prevent hypothermia by maintaining core body temperature when blood circulates over a special catheter placed in the central venous system [See Fig. 1].

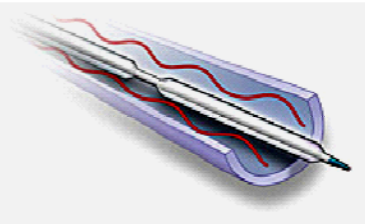

Figure 1. Illustration of endovascular warming via circulation of warm saline in a closed-loop circuit through balloons surrounding the catheter.

Figure 2. A catheter-based intravascular temperature management products that address an unmet clinical need for effective, accurate, easy-to-use and cost-effective control of body temperature in critical care patients

Clinical History

A 36-yr-old female with 56% total body surface area (TBSA) burn presented for initial excision and grafting. Prior to the traumatic events surrounding her injury, the patient's medical and surgical history included Raynaud's disease, asthma, melanoma, and shoulder surgery. Outpatient medications included albuterol nebulizers. On arrival to the Burn OR, she was classified an ASA IVE in accordance with her traumatic history which included:

- 56% TBSA thermal burn
- Inhalational injury
- Anemia to a hematocrit of 25%
- Thrombocytopenia to platelet count of 74k mg/dL
- 16.5 liters for 24 hour fluid resuscitation (preoperative)
- Escharotomies of bilateral forearms, hands and fingers
- Hypotensive shock requiring vasoactive drips to maintain mean arterial pressures > 55 mmHg

Intraoperative Results

After review of the patient's comorbidities and following discussion with the surgical team, an ICY® 38 cm 9.3 French central venous catheter (Alsius Corporation, Irvine, CA) was placed in the right femoral vein in standard aseptic technique preoperatively. This catheter was then connected to the ThermoGard™ system (Alsius Corporation, Irvine, CA), which was set for intravascular warming with maximum flow rate and a target temperature of 100.4 °F During the 4 hour procedure, normothermia was maintained between 96.8 °F to 100.2 °F. The ThermoGard™ 3000 ® IVTM and aggressive warming measures [coverage of body surface area as available, heat/moisture exchanger in the anesthesia circuit, and IV fluid warmer] were used in the OR. The room temperature was able to be maintained at 86.0 °F, down from standard Burn OR temperature setting of 102.0 °F using conventional warming methods. An uneventful operative course was noted.

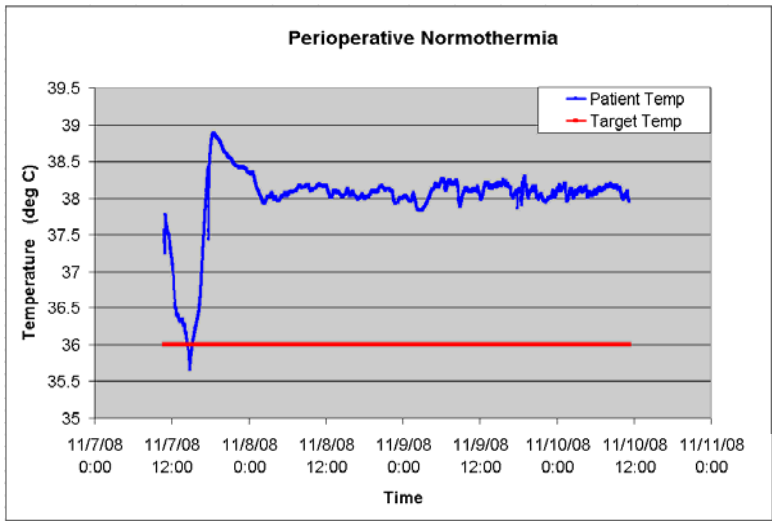

Figure 3.
Intraoperative IVTM during burn surgery.

Red line is indicative of the target temperature. Target temperature was 36.0 °C.

Blue line represents the patient's perioperative core temperature trend during burn excision and grafting procedure.

Postoperative Results

At completion of the case, the ThermoGard™ was disconnected from the patient and transported to the ICU. Intraoperative fluids administered in total were 8 liters crystalloid, 500cc hextend, 11 units packed red blood cells, 9 units fresh frozen plasma and 2 six-pack of platelets. Fluid losses for the case were estimated to be 3200 cc blood loss and 550 cc urine output. The first documented core temperature postop in the ICU was 97.2 °F, and the patient was reconnected to the ThermoGard™ warming unit for core temperature maintenance above 96.8 °F. IVTM was continued for 48 hours prior to catheter removal.

Summary

- Perioperative maintenance of normothermia is critical for prevention of ischemia in patients with Raynaud's disease scheduled for major burn surgery.
- Historically, normothermia has been an extremely elusive goal during burn surgery.
- The increase in morbidity and mortality associated with unintentional perioperative hypothermia warrants further investigation into warming strategies for burn patients with peripheral vascular disease (PVD).
- Future perioperative studies in burn patients with PVD are needed to detect the clinical dividends of IVTM regarding decreased surgical wound infections, decreased digit and limb ischemia, improved graft take, decreased hospitalization costs, decreased blood loss, decreased transfusion risks and improved metabolism.
- Utilization of the ThermoGard™ intravascular warming system and ICY® central venous catheter for IVTM prevented intraoperative hypothermia during this very large burn excision.
- We believe IVTM will help demonstrate the benefits of avoiding perioperative hypothermia in patients with PVD during burn surgery.

Literature cited -

Doufas AG. Consequences of inadvertent perioperative hypothermia. Best Practice & Research Clinical Anaesthesiology 17: 535-549, 2003.

Hoedemaekers et al. Comparison of different cooling methods to induce or maintain normo- or hypothermia in ICU patients: a prospective intervention study. Critical Care 11: R91, 2007.

Merchant et al. Therapeutic hypothermia after cardiac arrest: Unintentional overcooling is common using ice packs and conventional cooling blankets. Critical Care Medicine 32: S490-S494, 2006.

Stoelting et al. Peripheral Vascular Disease.Anesthesia and Co-Existing Disease. 4th ed. 2002. 165-166.

For further information contact:

Peter A. DeSocio, DO
Assistant Chief of Anesthesia
US Army Institute of Surgical Research
Clinical Division / Burn Center
3400 Rawley E. Chambers Ave.
Fort Sam Houston, TX 78234
Email: peter.desocio@amedd.army.mil