# PHOTOPLETHYSMOGRAM FEATURES TRACK REDUCTIONS IN CENTRAL BLOOD VOLUME IN A HUMAN MODEL OF PRE-SHOCK HEMORRHAGE

**SP McGrath[1], KL Ryan[2], SM Wendelken[1], CA Rickards[2], VA Convertino[2]**

[1]Thayer School of Engineering, Dartmouth College, Hanover, NH; [2]US Army Institute of Surgical Research, Fort Sam Houston, TX

The use of Army medical and/or other Army records in the preparation of this material is acknowledged, but is not to be construed as implying official Department of the Army approval of the conclusions presented.

## ABSTRACT

Objective: Changes in photoplethysmogram (PPG) characteristics may provide an early indication of blood loss in the hemorrhaging patient, prior to changes in standard vital signs. Various features of the PPG have been assessed during hypovolemia, but primarily in studies where subjects experienced only moderate blood loss or where patients were undergoing medical treatment and concurrently receiving pharmacological agents (e.g., anesthesia). The primary objective of this study was to test the hypothesis that alterations in the height, width and area under the curve (AUC) of the PPG pulse wave would track progressive reductions in central blood volume in the absence of pharmacological interventions. Methods: PPG data from finger, forehead, and ear pulse oximeter sensors were collected from 18 healthy subjects undergoing progressive reduction in central blood volume induced by lower body negative pressure (LBNP). Pulse height, width and AUC were calculated from each pulse wave recording. Results: Reductions in pulse height, width and AUC in the ear and forehead locations were strongly correlated with progressive reductions in stroke volume during LBNP ($R^2 \geq 0.73$), while correlations in PPG parameters from the finger oximeter were not as high ($R^2 \geq 0.18$). Changes in PPG parameters were observed before profound decreases in blood pressure. The best correlations between pulse parameters and stroke volume were obtained from the PPG of the forehead sensor ($R^2 \geq 0.76$). Conclusions: These results support the use of PPG waveform analysis as a potential diagnostic tool to detect clinically significant hypovolemia prior to the onset of cardiovascular decompensation.

## BACKGROUND

- Hemorrhage is a leading cause of death in both civilian and military trauma [1, 2]
- Accepted clinical methods for tracking blood volume (e.g., blood pressure via cannula) are generally invasive, may be prone to complications and change late in the course of hemorrhage due to physiological compensation
- Previous studies have shown that characteristics of the photoplethysmogram (PPG) may provide a reliable indication of hemodynamic changes, including hypovolemia, but were limited by use of:
  - Anesthetized surgical patients[3-5]
  - Only moderate blood loss (e.g., 450 ml blood donation) in healthy subjects [6]
- The current study uses the lower body negative pressure (LBNP) model of simulated hemorrhage to explore the effectiveness of PPG parameters in tracking central hypovolemia in conscious, healthy human subjects

## HYPOTHESIS

**Characteristics of the PPG pulse wave are associated with progressive reductions in central blood volume during LBNP.**

## METHODS

- Subjects: Eighteen healthy, nonsmoking subjects (8 males, 10 females) with mean ± SEM age of 23 ± 1 yrs, body weight of 69 ± 3 kg, and height of 171 ± 2 cm
- Progressive LBNP leading to hemodynamic decompensation (i.e., precipitous fall in BP and/or onset of presyncopal symptoms) (Fig. 1)
- Measurements:
  - Nonin® Pulse Oximeters on ear, finger and forehead→ PPG, oxygen saturation ($SpO_2$); PPG characteristics extracted (Fig. 2)
  - Finometer® → beat-to-beat arterial blood pressure
  - Thoracic electrical bioimpedance → stroke volume (SV)

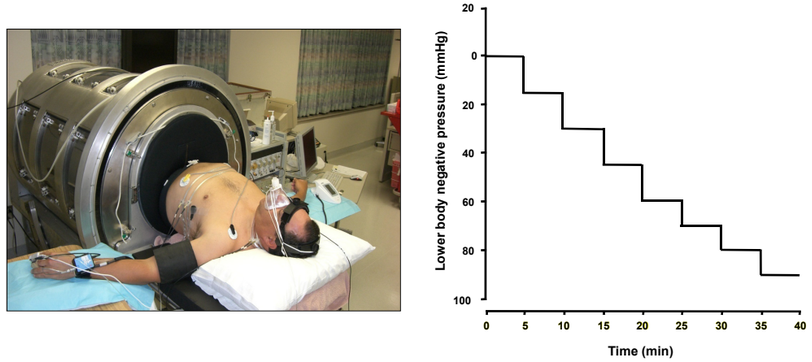


**Figure 1**. Subject in the LBNP device and the experimental protocol.

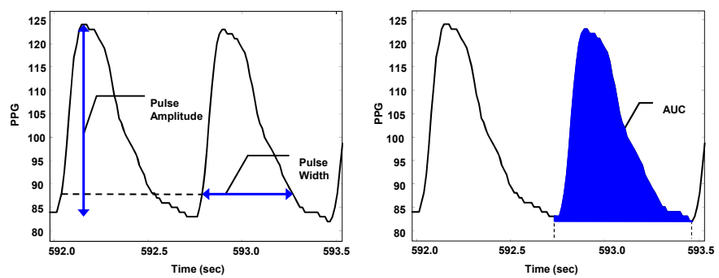


**Figure 2**. Illustration of pulse amplitude, pulse width and area under the curve (AUC) extracted from the PPG waveform.

## RESULTS

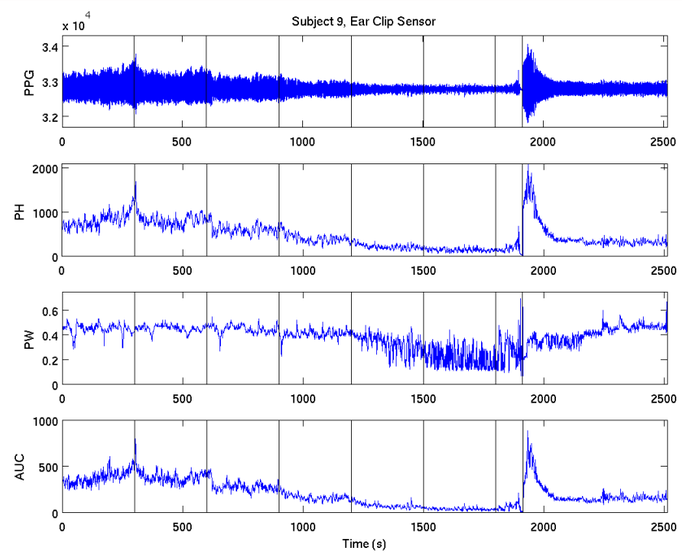


**Figure 3.** Representative tracings from a single subject of the ear PPG waveform; Pulse amplitude (PH), Pulse Width (PW), and area under the curve (AUC). Vertical lines denote pressure changes of the LBNP chamber. The final vertical line denotes the onset of presyncope.

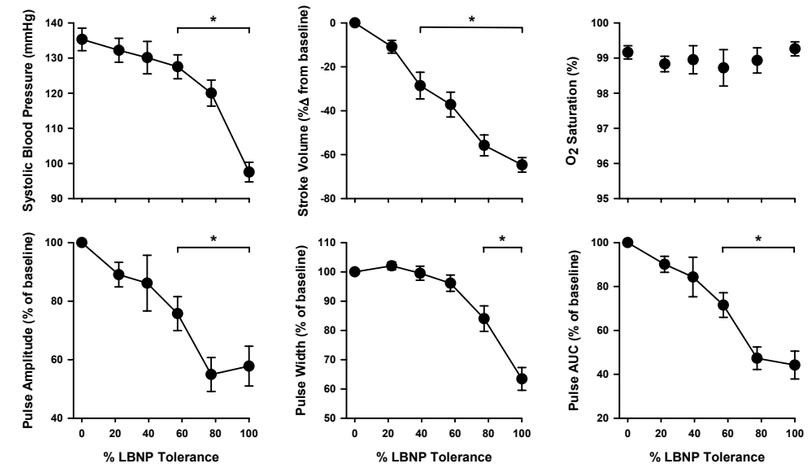


**Figure 4.** Hemodynamic and PPG data (forehead sensor) throughout the LBNP protocol. Due to inter-subject variation in LBNP time to hemodynamic decompensation, responses to LBNP were reapportioned to equal fractions between 0% maximum LBNP (baseline) and 100% maximum LBNP. *p≤0.02 compared with baseline value. Data are means ± SE.

**Table 1**. Amalgamated correlation coefficients ($R^2$) derived from linear regression analysis of changes in PPG pulse characteristics with changes in stroke volume measurements.

| PPG Parameter | Ear | Finger | Forehead |
|---|---|---|---|
| Pulse Amplitude | 0.73 | 0.60 | 0.91 |
| Pulse Width | 0.75 | 0.93 | 0.76 |
| AUC | 0.98 | 0.18 | 0.95 |

## CONCLUSIONS

- We found correlations ($R^2$) ≥ 0.73 between changes in stroke volume and PPG pulse amplitude, pulse width and AUC during LBNP in the ear and forehead sensors, with the best correlations between changes in stroke volume and AUC (0.98 from ear sensor and 0.95 from forehead sensor).
- These strong correlations during LBNP support our hypothesis that PPG waveform characteristics obtained from a standard pulse oximeter may prove to be sensitive and specific early indicators of blood loss in patients with compensatory hemorrhage.
- Our data indicate that PPG characteristics may be useful for monitoring trauma patients during the early, dynamic phase of hemorrhagic injury.

## REFERENCES

1. Bellamy RF. The causes of death in conventional land warfare: implications for combat casualty care research. *Mil Med.* 1984;149:55-62.
2. Sauaia A, Moore FA, Moore EE, et al. Epidemiology of trauma deaths: a reassessment. *J Trauma.* 1995;38:185-193.
3. Awad AA, Stout RG, Ghobashy MA, et al. Analysis of the ear pulse oximeter waveform. *J Clin Monit Comput.* 2006;20:175-184.
4. Awad AA, Ghobashy MA, Stout RG, et al. How does the plethysmogram derived from the pulse oximeter relate to arterial blood pressure in coronary artery bypass graft patients? *Anesth Analg.* 2001;93:1466-1471.
5. Partridge BL. Use of pulse oximetry as a noninvasive indicator of intravascular volume status. *J Clin Monit.* 1987;3:263-268.
6. Gesquiere MJ, Awad AA, Silverman DG, et al. Impact of withdrawal of 450 ml of blood on respiration-induced oscillations of the ear plethysmographic waveform. *J Clin Monit Comput.* 2007;21:277-282.